

# Fracture Diaphyseal Femur in a Case of Ipsilateral Excision Arthroplasty of Hip: Report of Two Cases with Description of an Unusual Injury Pattern, Mechanism, and Clinical Decision-making in Management

Kunal Shah<sup>1</sup>, Tushar Ubale<sup>1</sup>, Rahematullah Abdul<sup>1</sup>, Vaibhav Kasodekar<sup>2</sup>, Ashish Assudani<sup>1</sup>,  
Kiran Makwana<sup>1</sup>

## What to Learn from this Article?

Risk factors and management of fracture diaphyseal femur following ipsilateral nonunion neck femur or resection arthroplasty of hip.

## Abstract

**Introduction:** Although fracture diaphyseal femur is commonly seen in orthopedic practice, its association with ipsilateral resection arthroplasty of hip/pseudarthrosis of neck is rare. The technique of excision arthroplasty has undergone modification with emphasis on preserving as much bone as possible. However, it is not always possible to preserve bone while removing the earlier prosthesis and cement. This often leads to extensive proximal bone loss. Associated ipsilateral fracture femur presents a unique scenario. Till date, only one case report is published highlighting its surgical management.

**Case Report:** We report two cases of diaphyseal fracture femur associated with resection arthroplasty of hip at subtrochanteric level with greater trochanter as a separate fragment (Case 1) and other with pseudarthrosis of the neck of femur with intact greater trochanter (Case 2). The first case was operated with surface fixation, whereas the second was operated with closed antegrade intramedullary nail.

**Conclusion:** Decision-making and formulating treatment plan includes taking various factors into account such as level of resection arthroplasty of hip/pseudarthrosis of neck, status of greater trochanter (intact or separate fragment), osteoporosis, and post-operative ambulation and rehabilitation. In this report, we highlight the unusual occurrence, probable mechanism of injury, risk factors for fracture, and decision-making in the surgical management of such a condition.

**Keywords:** Diaphysis fracture, resection arthroplasty, pseudarthrosis, surface fixation, intramedullary nailing.

Access this article online

Website:  
www.jocr.co.in

DOI:  
2250-0685.598

## Author's Photo Gallery



Kunal Shah



Tushar Ubale



Rahematullah Abdul



Vaibhav Kasodekar



Ashish Assudani



Kiran Makwana

<sup>1</sup>Department of Orthopaedics, R. N. Cooper Hospital, Mumbai, Maharashtra, India, <sup>2</sup>Department of Orthopaedics, Sushrut Hospital, Mumbai, Maharashtra, India.

## Address of Correspondence

Dr. Kunal Shah,  
Department of Orthopaedics, R. N. Cooper Hospital, Mumbai, Maharashtra, India. Phone: +91-9930731911.  
E-mail: orthokunal@yahoo.com

Copyright © 2016 by Journal of Orthopaedic Case Reports

Journal of Orthopaedic Case Reports | pISSN 2250-0685 | eISSN 2321-3817 | Available on www.jocr.co.in | doi: 10.13107/jocr.2250-0685.598  
This is an Open Access article distributed under the terms of the Creative Commons Attribution Non-Commercial License (<http://creativecommons.org/licenses/by-nc/3.0>) which permits unrestricted non-commercial use, distribution, and reproduction in any medium, provided the original work is properly cited.

## Introduction

Fracture shaft femur is a commonly encountered injury in day to day practice. Orthopedic surgeons are well versed with the management of this type of injury. It usually occurs following road traffic accidents. Pathological femoral shaft fractures are mainly attributed to osteoporosis, preexisting femoral pathology, etc. [1, 2].

Uncommonly, there can also be stress fractures of the diaphysis of femur. Treatment includes intramedullary nailing or surface fixation depending on the age, etiology of fracture, surgeon's preference, and clinical scenario [3].

Resection arthroplasty of hip includes removal of necrotic bone in proximal femur along with the prosthesis and cement if present. Although uncommonly done nowadays, it is described as a treatment option in cases of periprosthetic recalcitrant infection, septic sequelae, recurrent hip dislocation, etc. [4]. Pseudarthrosis of neck of femur is a common occurrence because of precarious blood supply to neck of femur, lack of cambium layer in periosteum, inadequate fixation, lack of anatomical reduction, etc. [5]. Resection arthroplasty of hip and pseudarthrosis of neck presents as loss of proximal fulcrum for fracture diaphysis of femur to occur.

We present two cases with the unique scenario of fracture diaphyseal femur concurrent with resection arthroplasty of hip/pseudarthrosis neck of femur operated surgically. Till date, only one similar case is reported of subtrochanteric fracture in femur post-girdlestone arthroplasty treated with intramedullary nail [6]. In this report, we intend to highlight the unusual occurrence, probable mechanism of injury, risk factors, and clinical decision-making in the surgical management of such a condition.

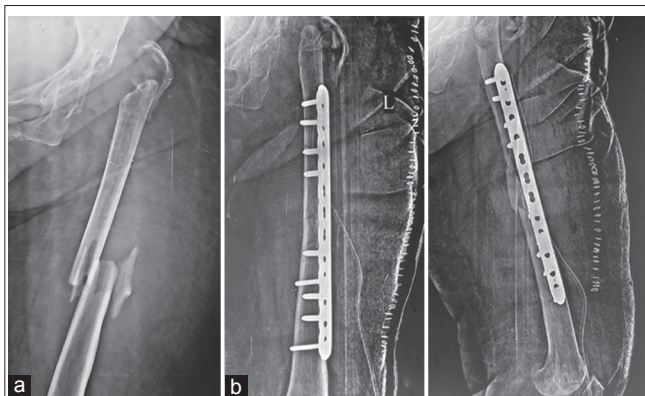
## Case Reports

### Case 1

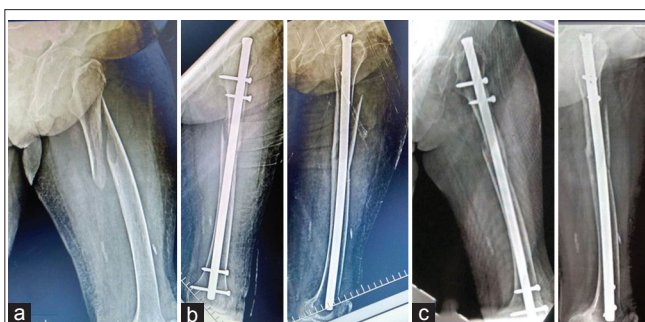
A 70-year-old lady came to trauma center with pain and swelling in the left thigh. She gave history of slip and fall at home with thigh directly hitting the table. Radiographs of thigh suggested diaphyseal fracture left shaft femur with greater trochanter as a separate fragment and ipsilateral excision arthroplasty of the hip (Fig. 1a). There was no other associated injury, and distal neurovascular examination was within normal limits. She had resection arthroplasty done in ipsilateral hip 15 years ago for an infected total hip replacement arthroplasty (cemented). Before fall, she was walking full weight bearing with shoe raise and stick support. She did not have any comorbidities. There was no finding suggestive of pathological fracture other than osteoporosis. After optimizing the patient, she was offered surgery in the form surface fixation. She was operated in the form of open reduction internal fixation with locking compression plate (Fig. 1b).

### Case 2

A 65-year-old lady presented with spiral proximal diaphyseal fracture following a trivial fall at home. Further radiographs suggested that she had pseudarthrosis at neck of femur due to neglected fracture neck of femur (Fig. 2a). She was full weight bearing ambulating since last 10 years without any pain. However, she used shoe raise and stick while walking. There were no comorbidities. After adequate pre-operative work up and planning, she was operated with closed intramedullary nailing (Fig. 2b).



**Figure 1:** (a) Radiograph showing fracture shaft femur with butterfly fragment and ipsilateral resection arthroplasty done with greater trochanter as separate fragment. (b) Immediate post-operative radiograph showing fracture fixation with locking compression plate.



**Figure 2:** (a) Radiograph showing spiral fracture proximal diaphysis femur with ipsilateral pseudarthrosis of neck of femur. (b) Immediate post-operative radiograph showing fracture fixation with intramedullary nail. (c) 3-month follow-up radiograph showing callus formation in Case 2.

### Post-operative protocol

After surgery, both patients were mobilized nonweight bearing for 6 weeks followed by gradual weight bearing walking. Knee range of motion exercises and quadriceps strengthening was started in immediate post-operative phase. At 3 months, radiograph showed good callus formation and full weight bearing walking was started (Fig. 2c). Presently, at 1 year follow-up, both patients are full weight bearing walking with a stick support and full range of motion of the knee. Limb length discrepancy was same as before surgery.

## Discussion

The mechanism of injury in case of femoral diaphyseal fractures is usually due to direct blow to femoral shaft. Femur like other bones gives away in tension, depending on the direction of force. Elderly patients typically present with spiral fracture due to torsional forces, whereas axial and bending forces act on young patients to produce fractures [7]. In Case 1, since there was a resection arthroplasty of hip done and in Case 2, there was pseudarthrosis at neck of femur suggesting loss of fulcrum proximally for axial, bending, or torsional forces to act and produce fractures. Therefore, biomechanically, there were fewer chances of fracture. We feel that probable mechanism in Case 1 was direct blow to femur due to fall, and in Case 2, it was twisting injury due to fall. The long-standing fibrosis

would have provided enough leverage for torsional forces to act and produce spiral fracture in pathologically weak bone. Moreover, the femur bone appeared to be weakened due to senile osteoporosis and previous attempt of cement removal during resection arthroplasty (Case 1). Dunn *et al.* cited similar risk factors of weakening of bone for subtrochanteric fracture in their case [6].

The goal of resection arthroplasty is to create stable pseudarthrosis site with eradication of infection and pain. Resection arthroplasty of hip leads to instability, limb length discrepancy, abductor weakness, etc. The majority of patients require some form of ambulation assistance [8]. The technique of girdle stone arthroplasty has undergone modification with emphasis on preserving as much bone as possible [4, 9]. However, it is not always possible to preserve bone while removing the earlier prosthesis and cement. In Case 1, resection arthroplasty lead to severe bone loss with excision of the proximal end of femur up to subtrochanteric level.

Management of this unique case scenario posed several challenges. Clinical decision-making in formulating treatment plan included taking various factors into account such as the presence of resection arthroplasty of hip at subtrochanteric level with greater trochanter as a separate fragment (Case 1), pseudarthrosis at neck of femur with intact greater trochanter (Case 2) osteoporosis, and post-operative ambulation and rehabilitation. As in Case 1, the greater trochanter was not intact, so we did not choose an intramedullary interlocking nail. Furthermore, there was a concern about disturbing a stable pseudarthrosis site while doing intramedullary nailing. In case described by Dunn *et al.*, the greater trochanter was intact and they performed open intramedullary nailing. However, they cited several problems like getting a closed reduction due to lack of adequate traction

and difficulties in reaming the canal [6]. Retrograde femoral nailing could have been an option in such cases if intramedullary device is preferred and greater trochanter is shattered. However, this method would also pose problems with traction and getting a closed reduction. Furthermore, there was concern about opening the knee joint which is already arthritis in old age. For these reasons, we chose plate fixation as a modality of fracture fixation. As the fixation was stable and proximal pseudarthrosis site was not disturbed, we could start early joint mobilization and subsequently patient returned to pre-operative ambulatory status. In Case 2, since the greater trochanter was intact, we preferred intramedullary fixation. There were difficulties with traction and getting a closed reduction. However, the main advantage was that biology of fracture was preserved due to closed technique which aids in union.

### Conclusion

Thus, we conclude that ipsilateral diaphyseal femur fracture with resection arthroplasty/pseudarthrosis is a rare case scenario. Risk factors leading to such a complication should be borne in mind. The case requires careful consideration and analysis of various factors in formulating the plan of management.

### Clinical Message

Fracture diaphyseal femur can occur after following nonunion neck femur or resection arthroplasty of hip. Risk factors leading to this should be understood and analyzed. Meticulous planning taking various factors into account should be done.

### References

1. Lenart BA, Neviasser AS, Lyman S, Chang CC, Edobor-Osula F, Steele B, *et al.* Association of low-energy femoral fractures with prolonged bisphosphonate use: A case control study. *Osteoporos Int* 2009;20(8):1353-1362.
2. Boden BP, Speer KP. Femoral stress fractures. *Clin Sports Med* 1997;16(2):307-317.
3. Beaty JH. Operative treatment of femoral shaft fractures in children and adolescents. *Clin Orthop Relat Res* 2005;434:114-122.
4. Hudec T, Jahoda D, Sosna A. Resection hip arthroplasty – Mid - And long-term results. *Acta Chir Orthop Traumatol Cech* 2005;72(5):287-292.
5. Marti R, Raaymakers EL, Nolte P, Besselaar PP. Pseudarthrosis of the proximal femur. *Orthopade* 1996;25(5):454-462.
6. Dunn J, Scully WF, Crawford DA, Manoso MW. Ipsilateral diaphyseal femur fracture after resection arthroplasty. *J Arthroplasty* 2012;27(8):1580.e17-19.
7. Tencer AF, Kaufman R, Ryan K, Grossman DC, Henley BM, Mann F, *et al.* Femur fractures in relatively low speed frontal crashes: The possible role of muscle forces. *Accid Anal Prev* 2002;34(1):1-11.
8. Sharma H, De Leeuw J, Rowley DI. Girdlestone resection arthroplasty following failed surgical procedures. *Int Orthop* 2005;29(2):92-95.
9. Esenwein SA, Robert K, Kollig E, Ambacher T, Kutscha-Lissberg F, Muhr G. Long-term results after resection arthroplasty according to Girdlestone for treatment of persisting infections of the hip joint. *Chirurg* 2001;72(11):1336-1343.

Conflict of Interest: Nil  
Source of Support: None

### How to Cite this Article

Shah K, Ubale T, Abdul R, Kasodekar V, Assudani A, Makwana K. Fracture Diaphyseal Femur in a Case of Ipsilateral Excision Arthroplasty of Hip: Report of Two Cases with Description of an Unusual Injury Pattern, Mechanism, and Clinical Decision-making in Management. *Journal of Orthopaedic Case Reports* 2016 Sep-Oct;6(4): 111-113.