

# Charcot Fracture in the Calcaneus after Total Knee Arthroplasty: A Case Report

Hirokazu Takai<sup>1</sup>, Katsuhiko Kiyota<sup>1</sup>, Nobutake Nakane<sup>1</sup>, Tomoki Takahashi<sup>1</sup>

## What to Learn from this Article?

Calcaneal stress fracture may occur after total knee arthroplasty in patients with neuropathic disorders such as a Charcot joint disease.

## Abstract

**Introduction:** Only a few reports have described calcaneus fractures after total knee arthroplasty (TKA). Therefore, in this report, we describe a case of calcaneal avulsion fracture that occurred 5 weeks after a TKA in a relatively young male patient with syphilis.

**Case Report:** A 63-year-old man with syphilis had Charcot joint of the right knee. The patient developed severe varus deformity and contracture and experienced severe pain in the knee. TKA was performed to alleviate the pain and improve the patient's gait. The patient noticed slight heel pain 4 weeks after the TKA, and a calcaneus avulsion fracture in the ipsilateral foot was diagnosed without any trauma 1 week later. Open reduction internal fixation was performed with cannulated cancellous screws and a cerclage wire. 3 weeks after the surgery, partial weight bearing was permitted in an orthotic device. Full weight-bearing was allowed at 7 weeks after surgery. The surgical wounds healed without complications. The calcaneus fracture successfully achieved bone union with appropriate surgical intervention and aftercare.

**Conclusion:** The previous studies have shown that calcaneus stress fracture may occur in elderly osteoporotic women after TKA. Patients with peripheral neuropathy may develop a Charcot fracture after minimal trauma because of decreased protective sensation, even if the patient is a relatively young man without osteoporosis. Charcot joint disease is also considered to be a risk factor for calcaneal stress fracture and Charcot fracture after TKA.

**Keywords:** Charcot fracture, total knee arthroplasty, stress fracture, calcaneus fracture

## Introduction

Some studies report stress fractures after total knee arthroplasty (TKA). Fractures of the pelvis (pubis and ischium), femoral neck, subtrochanteric femur, patella, tibia, and metatarsal bones have all been reported [1, 2, 3]. However, only a few studies have described

calcaneus fractures after TKA [4, 5]. These fractures do not occur in relatively young men without osteoporosis, but in elderly women with osteoporosis [4]. In this report, we describe a case of calcaneal avulsion fracture that occurred 5 weeks after a TKA in a relatively young male patient with syphilis.

### Access this article online

Website:  
www.jocr.co.in

DOI:  
2250-0685.650

### Author's Photo Gallery



Dr. Hirokazu Takai



Dr. Katsuhiko Kiyota



Dr. Nobutake Nakane



Dr. Tomoki Takahashi

<sup>1</sup>Department of Orthopaedic Surgery, Kumamoto Kinoh Hospital, Yamamuro, Kitaku, Kumamoto 860-8518, Japan.

### Address of Correspondence

Dr. Hirokazu Takai,

Department of Orthopaedic Surgery, Kumamoto Kinoh Hospital 6-8-1, Yamamuro, Kitaku, Kumamoto 860-8518, Japan.

Tel: +81-96-345-8111, Fax: +81-96-345-8188.

E-mail: hirokazoid@hotmail.co.jp

Copyright © 2016 by Journal of Orthopaedic Case Reports

Journal of Orthopaedic Case Reports | pISSN 2250-0685 | eISSN 2321-3817 | Available on www.jocr.co.in | doi: 10.13107/jocr.2250-0685.650

This is an Open Access article distributed under the terms of the Creative Commons Attribution Non-Commercial License (<http://creativecommons.org/licenses/by-nc/3.0>) which permits unrestricted non-commercial use, distribution, and reproduction in any medium, provided the original work is properly cited.

### Case Report

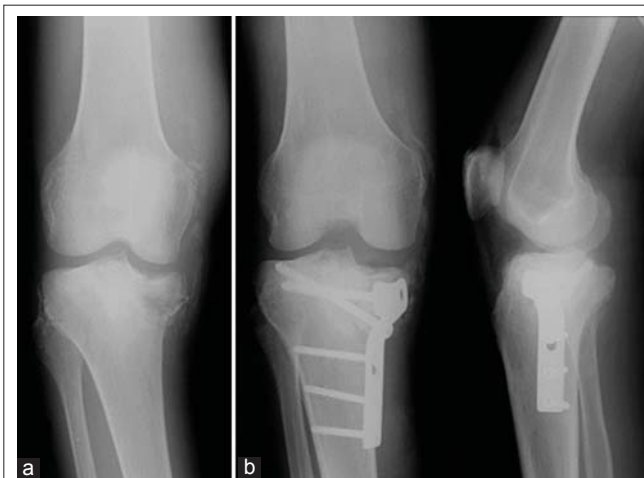A 63-year-old man with syphilis and a body mass index of 19.6 kg/m<sup>2</sup> presented with a painful swollen knee 1 month after slipping. Radiographs revealed a semi-acute depression fracture of the tibia with comparatively large defect of bone and some intra-articular loose bodies considering the pain. He had deep tendon hyporeflexia, hypo pallesthesia, disturbance of deep sensibility, and decreased protective sensation due to tabes dorsalis. Therefore, his right knee was diagnosed as a Charcot joint disease. Open reduction and internal fixation (ORIF) using a conventional non-locking plate was performed (Fig. 1). Varus deformity and delayed bone union gradually developed after the procedure. At this point, his clinical depression worsened and was accompanied by abnormal behavior. The results of the blood test TPLA 6600 (TLHA 5120 X) had deteriorated to TPLA 22000 (TPHA 10240 X). Tabes dorsalis had been treated with antibiotics (ampicillin). Despite the treatment, the patient had to be transferred to a psychiatric hospital because of aggravated neurologic manifestations. He was diagnosed with organic mental disorder caused by tabes dorsalis and was hospitalized for 2 months. 1 year later, ORIF metal removal was performed.

About 10 years after the first knee symptoms, the patient visited our hospital because of right knee pain and an abnormal gait. Clinical examination showed severe varus deformity and limitation of the range of motion. TKA was carried out with LCCK® (Zimmer Biomet, Warsaw, IN, United States) (Fig. 2). The pain subsequently subsided and the patient had an improved range of motion in the knee. 4 weeks after the surgery, the patient experienced a slight pain in his right heel while walking. Radiographs did not reveal any obvious fractures (Fig. 3a). After a 1-week period of observation, plain radiographs showed an avulsion calcaneal fracture (Fig. 3b). This right calcaneus fracture was successfully treated with ORIF using two cannulated cancellous screws and a cerclage wire (Fig. 4a, b, c). 3 weeks after the surgery, partial weight bearing was permitted with a vacuum-stabilized orthosis (VACOPed®, OPED, Oberlindern, Germany) that allowed for angle adjustments at five-degree intervals. Full weight-bearing was allowed at 7 weeks after surgery. The surgical wounds healed without complications. 6 months after ORIF, bone union was eventually achieved and metal removal was performed. At the final follow-up, the patient was able to walk without difficulty. There has been no early loosening of the prosthesis so far.

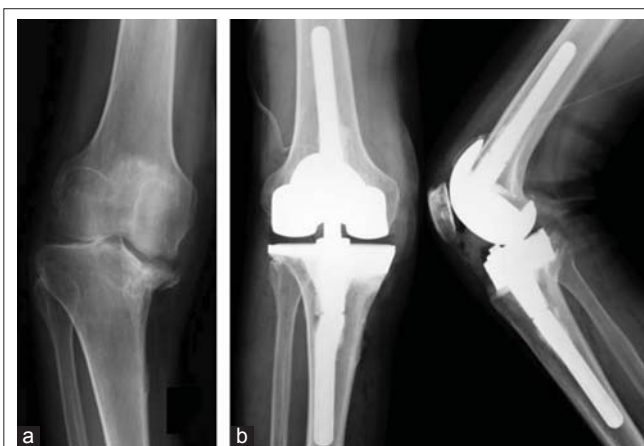### Discussion

Stress fractures can occur after TKA. Stress fractures of the pelvis (pubis and ischium), femoral neck, subtrochanteric femur, patella, tibia, and metatarsal bones have been reported [1, 2, 3]. However, to the best of our knowledge, only a few papers have described calcaneus fractures after TKA [4, 5]. Calcaneal stress fractures are rare and account for 1.3-2.7% of all cases of calcaneal fractures in the literature [6, 7]. Owing to their low incidence, little has been reported regarding these types of fractures, particularly after TKA.

The cause of calcaneus stress fractures after TKA has not been clearly understood; however, five mechanisms are considered: (1) The fragility of the calcaneus, caused by low activity preoperatively, (2) increased load on the calcaneus accompanying hyperactivity after a TKA performed to relieve knee pain, (3) marked change in the alignment of the lower extremity, (4) changing the foot contact point from the toes to the heel, and (5) strong traction force of the triceps surae muscle.



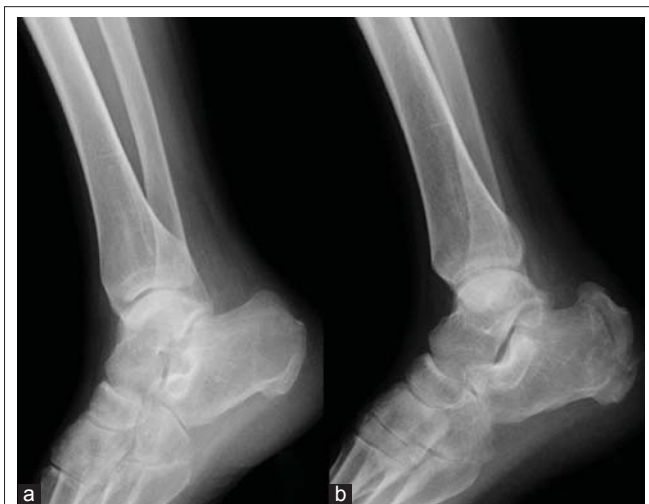**Figure 1:** (a) Radiograph of the right knee, showing a semi-acute depression fracture of the tibia with the lack of bone and some intra-articular loose bodies, (b) radiographs showing open reduction and internal fixation using a conventional non-locking plate.



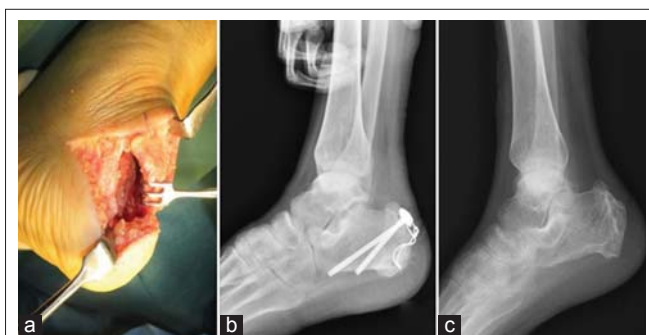
**Figure 2:** (a) Radiograph of the right knee showing severe varus deformity of the knee joint, (b) radiographs showing total knee arthroplasty using LCCK® (Zimmer Biomet, Warsaw, IN, United States).

Miki *et al.* reported five calcaneus fractures after total joint arthroplasty. In this study, the occurrence was <1%, and the risk factors for fracture were increased age, female sex, and osteoporosis. These calcaneus stress fractures occurred 6-10 weeks after TKA [4]. However, in this case, the patient was a relatively young man. His bone mineral density (femur) was 0.701 g/cm<sup>2</sup> and his young adult mean was 81%; therefore, the diagnostic criteria for osteoporosis were not fulfilled. Thus, it was considered that his calcaneal stress fracture was not caused by osteoporosis but related to some pathological factors.

Even in the absence of obvious osteoporosis or bone fragility caused by diabetes mellitus, pathological fractures, joint dislocation, or bone destruction may occur if central and/or peripheral nerve abnormalities are present. Patients with peripheral neuropathy may develop a calcaneal stress fracture after minimal trauma because of decreased protective sensation [8]. These neuropathic arthropathies were called Charcot joint disease.



**Figure 3:** (a) Radiograph of the right heel 4 weeks after total knee arthroplasty, showing no signs of fracture, (b) radiograph of the right heel 5 weeks after total knee arthroplasty, revealing a displaced calcaneus avulsion fracture.



**Figure 4:** (a) Intraoperative photograph showing pale cancellous bone and a displaced fragment of the calcaneus, (b) radiograph showing open reduction and internal fixation using two cannulated cancellous screws and a cerclage wire, (c) radiograph showing successful bone union with all metals removed.

Johnson stated the relationship between fractures and Charcot joint disease and called the fracture neuropathic fracture [9]. The fracture was considered an early pathological change to Charcot joint disease. Chantelau studied the relationship between diabetes mellitus and Charcot joint disease and called the fracture Charcot fracture [10]. The occurrence of Charcot fracture is reported as being between 0.1% and 2.5% of all diabetic patients [11, 12].

In fact, the patient in our report had deep tendon hyporeflexia, hypopallesthesia, disturbance of deep sensibility, and decreased protective sensation due to tabes dorsalis. Therefore, we diagnosed his calcaneal stress fracture as a Charcot fracture.

Concerning the treatment of the calcaneal stress fracture, early diagnosis and appropriate care must be performed as soon as possible [13]. Chantelau said that adequate treatment could heal Charcot fractures; however, if diagnosis is delayed, Charcot fracture may progress to Charcot joint disease [10]. The diagnosis of Charcot joint disease (Charcot fracture) is frequently delayed, because of mild symptoms. In addition, calcaneal stress fractures are often misdiagnosed as bursitis, plantar nerve entrapment syndrome, pseudogout, osteomyelitis, peroneal tendonitis, or plantar fasciitis [5]. Delayed diagnosis or misdiagnosis leads to catastrophic complications and makes the treatment more difficult. Surgical intervention for these calcaneal displaced fractures is often associated with a higher complication rate, including complications such as infection, skin necrosis, Achilles tendon rupture, or re-displacement of the bone fragment [13, 14]. Although Gehrman and Renard classified stress fracture of the calcaneus as a low-risk fracture, calcaneus fracture may lead to severe complications [15]. Based on this classification, the fracture was diagnosed Beavis Type I, therefore, we utilized cannulated cancellous screws and a cerclage wire for ORIF [6, 13, 14] and achieved a good result. If the Charcot fracture had developed to Charcot joint disease, arthrodesis of the ankle may be necessary. Magnetic resonance imaging in the early stage is indispensable to make an appropriate diagnosis and perform the adequate treatment.

### Conclusion

Although there are no risk factors for osteoporosis, calcaneal stress fracture may occur after TKA in patients with neuropathic disorders such as a Charcot joint disease. More careful post-operative observation is required in cases of TKA for Charcot joint disease. In addition, surgeons must recognize the possibility of Charcot fracture in calcaneus after TKA in Charcot joint disease.

### Clinical Message

Calcaneus stress fracture after TKA rarely happens in elderly osteoporotic women. By contrast, Charcot fractures in calcaneus after TKA is possible to occur in patient with peripheral neuropathy even if the patient is a relatively young man without osteoporosis.

## References

1. Hardy DC, Delince PE, Yasik E, Lafontaine MA. Stress fracture of the hip. An unusual complication of total knee arthroplasty. *Clin Orthop Relat Res* 1992;281:140-144.
2. Pankaj A, Malhotra R, Logani V, Bhan S. Bilateral femoral neck stress fractures following total knee arthroplasty: A case report and review of literature. *Arch Orthop Trauma Surg* 2007;127(7):549-552.
3. Petje G, Landsiedl F. Stress fracture of the tibia after total knee arthroplasty. *Arch Orthop Trauma Surg* 1997;116(8):514-515.
4. Miki T, Miki T, Nishiyama A. Calcaneal stress fracture: An adverse event following total hip and total knee arthroplasty: A report of five cases. *J Bone Joint Surg Am* 2014;96(2):e9.
5. Jeong M, Jin JW, Shin SJ, Kang BY. Calcaneal insufficiency fracture after ipsilateral total knee arthroplasty. *J Bone Metab* 2016;23(1):45-48.
6. Beavis RC, Rourke K, Court-Brown C. Avulsion fracture of the calcaneal tuberosity: A case report and literature review. *Foot Ankle Int* 2008;29(8):863-866.
7. Squires B, Allen PE, Livingstone J, Atkins RM. Fractures of the tuberosity of the calcaneus. *J Bone Joint Surg Br* 2001;83(1):55-61.
8. Biehl WC 3<sup>rd</sup>, Morgan JM, Wagner FW Jr, Gabriel R. Neuropathic calcaneal tuberosity avulsion fractures. *Clin Orthop Relat Res* 1993;296:8-13.
9. Johnson JT. Neuropathic fractures and joint injuries. Pathogenesis and rationale of prevention and treatment. *J Bone Joint Surg Am* 1967;49(1):1-30.
10. Chantelau E. The perils of procrastination: Effects of early vs. Delayed detection and treatment of incipient Charcot fracture. *Diabet Med* 2005;22(12):1707-1712.
11. Myerson MS, Edwards WH. Management of neuropathic fractures in the foot and ankle. *J Am Acad Orthop Surg* 1999;7(1):8-18.
12. Schon LC, Marks RM. The management of neuroarthropathic fracture-dislocations in the diabetic patient. *Orthop Clin North Am* 1995;26(2):375-392.
13. Banerjee R, Chao JC, Taylor R, Siddiqui A. Management of calcaneal tuberosity fractures. *J Am Acad Orthop Surg* 2012;20(4):253-258.
14. Takai H, Takahashi T, Takai S, Nakane N. Bilateral calcaneal avulsion fractures complicated with a delayed achilles tendon rupture in a patient with diabetes. *JBJS Case Connect* 2014;4(4):e121.
15. Gehrmann RM, Renard RL. Current concepts review: Stress fractures of the foot. *Foot Ankle Int* 2006;27(9):750-757.

Conflict of Interest: Nil  
Source of Support: None

## How to Cite this Article

Takai H, Kiyota K, Nakane N, Takahashi T. Charcot Fracture in the Calcaneus after Total Knee Arthroplasty: A Case Report. *Journal of Orthopaedic Case Reports* 2016 Nov-Dec;6(5):92-95.