

Accidental Bolt Gun Injury to Femur - A Case Report

Ravi Prasad Kattimani¹, Sanath Shetty², Humayun Mirza²

What to Learn from this Article?

The wound is primarily infected by the time the patient presents to the hospital. The wound should be explored as foreign bodies could be deeply embedded. Aggressive treatment with wound exploration, multiple wound debridement and intra venous antibiotics based on culture reports are the mainstay of treatment.

Abstract

Introduction: Bolt gun or slaughterer's guns are used in meat industry for "humane killing" of animals. Injuries caused by bolt gun are rare, reported exclusively from central European countries. We report a case of 28 year old male, who accidentally shot himself with a bolt gun to his right thigh.

Case Report: A 28 years old male presented to our Accident and Emergency department after accidental injury to his right thigh with bolt gun. He had an entry wound measuring 2 cm in length and 1 cm in breadth over anterior aspect of lower one third of thigh at lower and sustained Grade II compound fracture of right femur shaft at distal one third. The wound was treated with multiple debridements, negative pressure wound therapy and intravenous antibiotics based on culture and sensitivity.

Conclusion: Bolt gun or slaughterer's guns are weapons used in meat industry for slaughtering animals. Wounds inflicted by bolt guns have specific morphological feature, distinctive from wounds made by other kinds of hand firearms. Most of the time wound will be infected at presentation. Lesions caused by these weapons are likely to have a more serious character than is to be expected from the size of the entrance wound. The mainstay of treatment is liberal wound exploration, multiple debridement's and intra venous antibiotics based on culture reports to treat infection and prevent morbidity.

Key words: Bolt gun injury, slaughterer's gun, femur.

Introduction

Bolt guns (Fig. 1) are weapons used in meat industry for slaughtering animals. It causes immediate loss of consciousness thus causing humanization of the process [1]. Injury with bolt gun is rare. Wounds inflicted by bolt guns have specific morphological features, distinctive from wounds made by other kinds of hand firearms. Most of the time wound will be infected at presentation. Lesions caused by these weapons

are likely to have a more serious character than is to be expected from the size of the entrance wound [3].

Case Report

A 28 year old male while attempting to slaughter a calf holding its head between his thighs accidentally shot himself with bolt gun to right thigh and sustained Grade II open fracture of distal one third shaft of femur

Access this article online
Website: www.jocr.co.in
DOI: 2250-0685.544

Author's Photo Gallery



Dr. Ravi Prasad Kattimani



Dr. Sanath Shetty



Dr. Humayun Mirza

¹Department of Trauma and Orthopedic, St. Georges Hospital, London, UK, ²Department of Trauma and Orthopedic, Glan Clwyd Hospital, Rhyl, UK.

Address of Correspondence

Dr. Ravi Prasad Kattimani,
Flat 37/1, Ingelby House, Black Shaw Road - SW17 0BZ, Tooting, London.
E-mail: raviprasad.kattimani@gmail.com

Copyright © 2016 by Journal of Orthopaedic Case Reports

Journal of Orthopaedic Case Reports | pISSN 2250-0685 | eISSN 2321-3817 | Available on www.jocr.co.in | doi:10.13107/jocr.2250-0685.544

This is an Open Access article distributed under the terms of the Creative Commons Attribution Non-Commercial License (<http://creativecommons.org/licenses/by-nc/3.0>) which permits unrestricted non-commercial use, distribution, and reproduction in any medium, provided the original work is properly cited.

(Fig. 2). He had an entry wound measuring 2 cm in length and 1 cm in breadth over anterior aspect of his right thigh (Fig. 3).

The wound was explored and debrided on the day of admission. Wound swab grew *Pseudomonas*, *Proteus* and *Anaerobes*. He was started on intravenous Augmentin. After five days, patient developed fever with chills and rigors. He also had purulent discharge from the wound. Inflammatory markers were raised with C reactive protein of 450. MRI (Fig. 4) confirmed there was no collection of pus in the posterior compartment of thigh. He underwent another wound exploration and debridement on fifth day of admission. Pus collection was found in the subcutaneous and sub muscular layers of right thigh. The wound was communicating with knee joint through the supra patellar pouch. Knee was washed out under arthroscopic guidance.

The wound was treated with negative pressure wound therapy. He had a further wound debridement and secondary wound closure after eleven days of injury and then discharged to home. The limb was immobilized in an above knee cast for four weeks and knee was later mobilized using a knee rafter splint.

He had three weeks of intravenous Ertepenem based on wound swab culture and sensitivity. At 12 months of follow up the wound healed with no signs of infection. He had full range of knee movements.



Figure 1: Bolt gun (picture source Wikipedia).

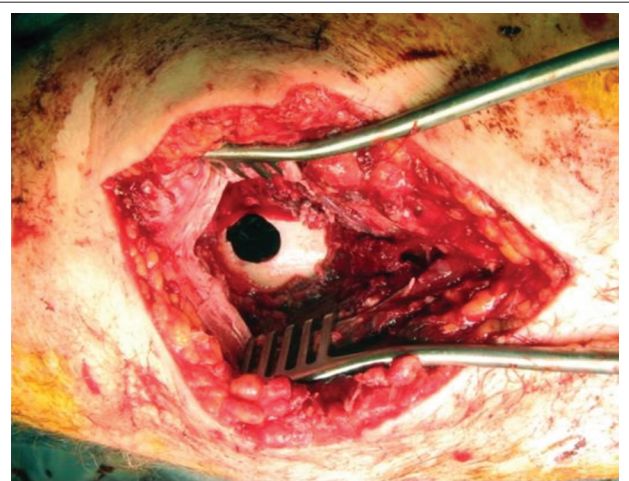


Figure 3: Intraoperative picture of the entry wound in femur.

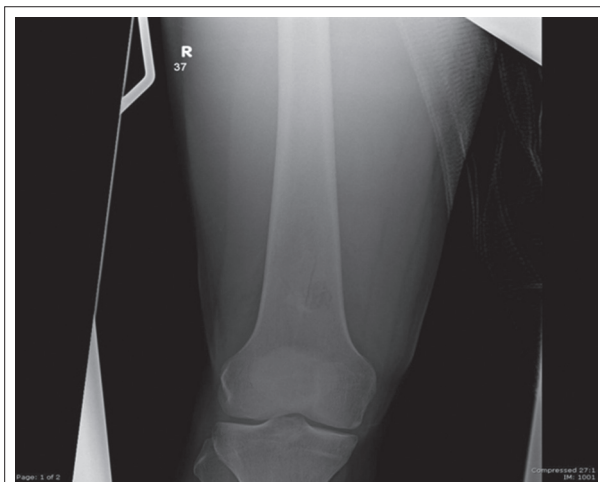


Figure 2: Radiograph of femur shows breach in distal one third of femur in anterior cortex.

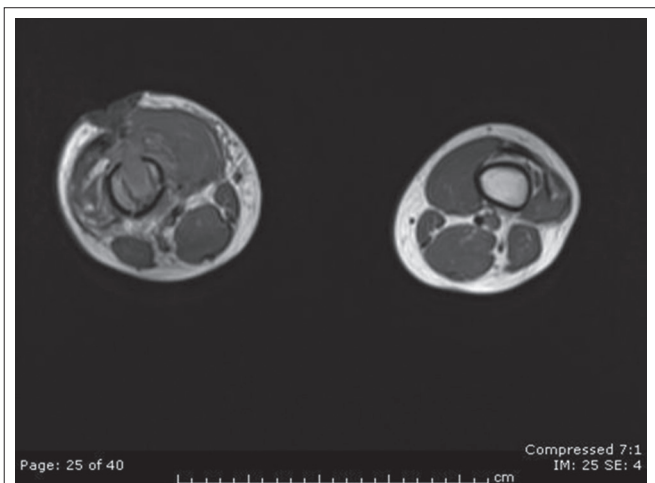


Figure 4: MRI of thigh.

Discussion

Injuries caused by bolt gun are rare, reported exclusively from central European countries [3] and cases are reported about their use in homicide [6, 7] and suicide [8, 9, 10] with mortality of more than 60%. [1, 2]. The death by bolt gun is by concussive force and penetration of the bolt [1].

The propulsive force of piston in bolt gun has such strength that lesions caused by these weapons are likely to have more serious complications than are to be expected from the size of entrance wound [3].

Wounds inflicted by bolt guns have specific morphological features, distinctive from wounds made by other kinds of hand firearms [10]. Selective features of bolt gun wounds are punched out round entrance and a double pattern of smoke soiling (wide zone of carbon deposition) [5]. Contamination of wound occurs by normal skin flora, clothes, water, soil and foreign bodies. These wounds are primarily infected with mixed bacterial flora of skin at the time of presentation to the hospital [3]. The dead tissue and debris form an excellent culture medium, leading to local proliferation of microorganisms; proliferation of bacteria can be demonstrated as early as six hours after injury [4].

The wounds caused by bolt gun injury must be explored to detect any foreign bodies, and all devitalized tissue must be excised to minimize risk of infection. Torn clothing will be often left behind deep inside the wound. So, it is essential to get detailed information about the clothing at time of injury, especially hand injuries as they often appear uncovered on arrival in the emergency department [3].

Conclusion

Accidental injury with bolt gun injury is rare. Wounds inflicted by bolt guns have specific morphological features, distinctive from wounds made by other kinds of hand firearms. The wound is primarily infected at the

time of presentation to the hospital. Aggressive treatment with wound exploration, multiple wound debridement and intra venous antibiotics based on culture reports are the mainstay of treatment to treat infection and prevent morbidity.

Clinical Message

For the surgeon treating bolt gun injuries it is imperative that a multiple wound debridement's are performed and a high index of suspicion of retained foreign bodies such as skin, soil and torn clothing should be maintained.

References

1. Mosdal C. Cranio-cerebral injuries from Slaughterer's gun. *Acta Neurochir (Wien)* 1985;74(1-2):31-34.
2. Gnjjidic Z, Kubat M, Malenica M, Sajko T, Radic I, Rumboldt Z. Epidemiological, forensic, clinical, and imaging characteristics of head injuries acquired in the suicide attempt with captive bolt gun. *Acta Neurochir (Wien)* 2002;144(12):1271-1277.
3. Tordrup PJ, Kjeldsen SR. Accidental injuries from captive-bolt guns (slaughterer's gun). *Injury* 1994;25(8):497-499.
4. Cooper GJ, Ryan JM. Interaction of penetrating missiles with tissues: Some common misapprehensions and implications for wound management. *Br J Surg* 1990;77(6):606-610.
5. Simic M, Draskovic D, Stojiljkovic G, Vukovic R, Budimlja ZM. The characteristics of head wounds inflicted by "humane killer" (captive-bolt gun) – A 15-year study. *J Forensic Sci* 2007;52(5):1182-1185.
6. Betz P, Pankratz H, Penning R, Eisenmenger W. Homicide with a captive bolt pistol. *Am J Forensic Med Pathol* 1993;14(1):54-57.
7. Caird J, Roberts G, Farrell M, Allcutt D. Self-inflicted head trauma using a captive bolt pistol: Report of three cases. *Br J Neurosurg* 2000;14(4):349-351.
8. Viel G, Schröder AS, Püschel K, Braun C. Planned complex suicide by penetrating captive-bolt gunshot and hanging: Case study and review of the literature. *Forensic Sci Int* 2009;187(1-3):e7-11.
9. Viola L, Costantinides F, Di Nunno C, Battista GM, Di Nunno N. Suicide with a butcher's bolt. *J Forensic Sci* 2004;49(3):595-597.
10. Grellner W, Buhmann D, Wilske J. Suicide by double bolt gunshot wound to the head: Case report and review of the literature. *Arch Kriminol* 2000;205(5-6):162-168.
11. Santín-Amo JM, Castro-Bouzas D, Arcos-Algaba A, Díaz-Cabanas L, Serramito-García R, Bandín-Diéguez FJ, et al. Intracranial injury caused by captive bolt gun. *Neurocirugía (Astur)* 2010;21(6):491-495.

Conflict of Interest: Nil
Source of Support: None

How to Cite this Article

Kattimani RP, Shetty S, Mirza H. Accidental Bolt Gun Injury to Femur - A Case Report. *Journal of Orthopaedic Case Reports* 2016 Sep-Oct;6(4):6-8.